Neuro-ophthalmic manifestations of pancreatic cancer

Andrew B Paxton, BMSc[1]; Jonathan A. Micieli, MD, FRCSC[2-5]

[1]Faculty of Medicine, University of Toronto, Toronto, ON, Canada, [2]Dept. of Ophthalmology and Vision Sciences, University of Toronto, Toronto, ON Canada, [3]Division of Neurology, Department of Medicine, University of Toronto, Toronto, ON, Canada, [4]Kensington Vision and Research Centre, Toronto, ON, Canada, [5]St. Michael's Hospital, Toronto, ON, Canada

Introduction

Pancreatic cancer is one of the deadliest cancers in North America with an overall 5-year survival rate of less than 10%.[1]

Pancreatic cancer may cause vision loss and neuro-ophthalmic symptoms due to metastasis to ocular structures such as the orbit, choroid, and very rarely, the optic nerve itself .[2]

Recognizing that neuro-ophthalmic symptoms may be secondary to metastasis in pancreatic cancer patients can result in rapid initiation of treatment, and potentially improve patient quality of life.

OBJECTIVE: To present a case series of patients with neuro-ophthalmic problems secondary to metastatic pancreatic cancer.

Case Presentations

CASE 1

69F with a 9-year history of metastatic pancreatic cancer.
Presenting with 10 days of painless vision loss in the left eye.

Pertinent Features on Examination:

- BCVA 20/20 OD, NLP OS
- Left RAPD

Investigations:

- MRI Orbits and Brain - Enhancement of both optic nerves and leptomeningeal enhancement in the brain.

Outcome:

- Whole brain radiotherapy (20Gy/5Fr).
- Death 3 months after treatment.

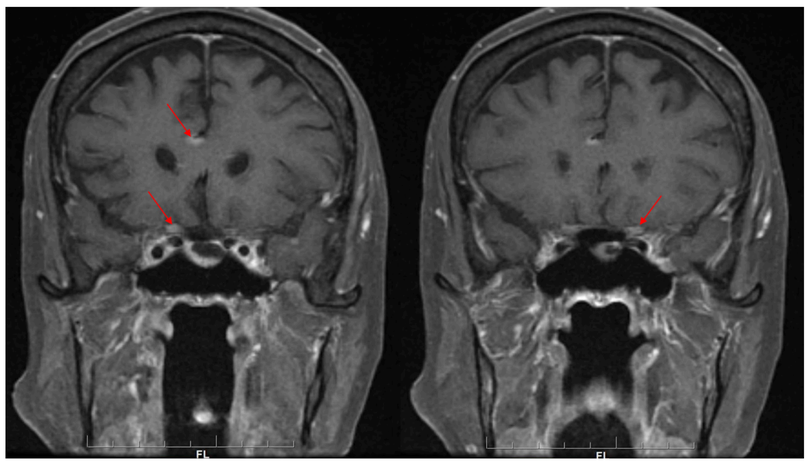

Figure 1. Magnetic resonance imaging (MRI) of the brain and orbits with contrast after vision loss demonstrating leptomeningeal enhancement (red arrows) including optic nerves.

CASE 2

62F with an 18-month history of metastatic pancreatic cancer.
1-month history of vertical diplopia and pain in the right eye.

Pertinent Features on Examination:

- Proptosis OD. Limited elevation and depression of the right eye.

Investigations:

- CT Orbits – Enhancing mass in the right inferior rectus muscle

Outcome:

- Radiation to right orbit (20Gy/5Fr). Death 1 month after treatment.

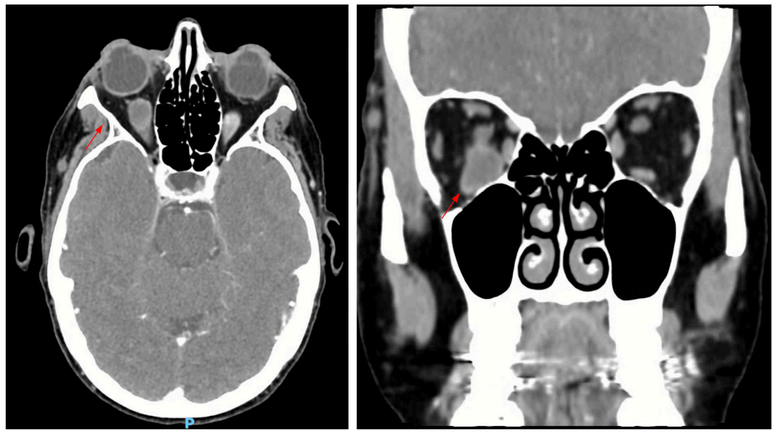

Figure 2. CT Orbits with contrast demonstrating an enhancing mass (red arrows) in the right inferior rectus muscle.

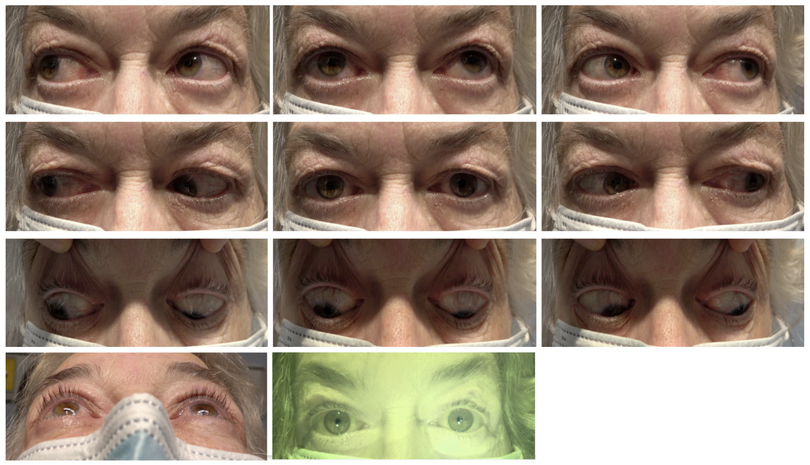

Figure 3. Examination of cardinal positions of gaze demonstrate limited depression and elevation of the right eye, as well as proptosis of the right eye.

CASE 3

75M with a 16-month history of metastatic pancreatic cancer.

Pertinent Features on Examination:

- BCVA 20/20 OU. Normal visual fields. Bilateral optic disc edema.

Investigations:

- MRI Orbits and Brain – Enhancement of optic nerve sheaths in both eyes, as well as leptomeningeal disease in the brain.

Outcome:

- Whole brain radiation (20Gy/5Fr). Normal VA 6 weeks after treatment.

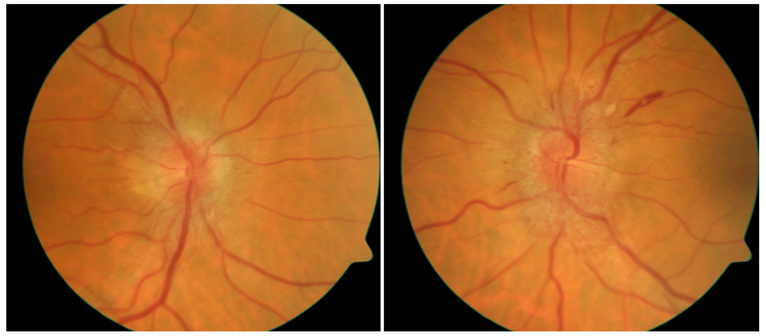

Figure 4. Fundus photos revealing bilateral optic disc edema.

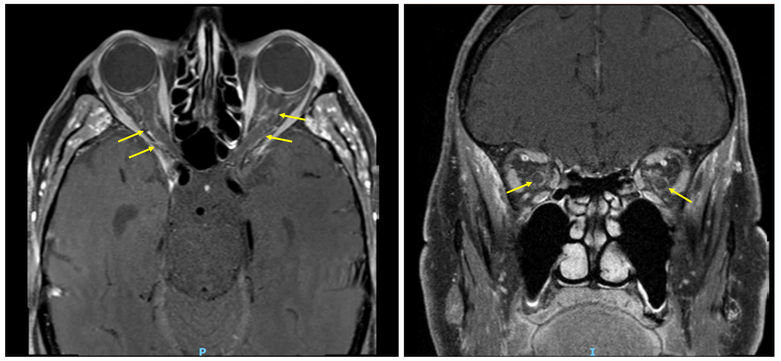

Figure 5. T1 MRI of the orbits with gadolinium and fat suppression demonstrating enhancement of the optic nerve sheaths (yellow arrows).

Discussion

With improving cancer detection and treatments, patients with aggressive cancers are living longer and presenting with metastases in atypical locations.

Pancreatic cancer rarely presents with neuro-ophthalmic manifestations and this is the largest case series to date.

We identified the optic nerve sheath as a site of metastasis in two cases of pancreatic cancer. In one case, it resulted in complete vision loss and in the other it resulted in bilateral optic disc edema and normal visual function. The orbit was last location of metastatic disease.

Early detection of these metastases can result in improved quality of life if radiation is instituted. However, they typically signal advanced disease and a short life expectancy.

References

1. Hidalgo M. Pancreatic cancer. *N Engl J Med.* 2010;362:1605-1617.
2. Shields CL, Welch RJ, Malik K, et al. Uveal metastasis: clinical features and survival outcome of 2214 tumors in 1111 patients based on primary tumor origin. *Middle East Afr J Ophthalmol.* 2018;25:81–90.